


Hoffmann® II Compact™ MRI

External Fixation System

Operative Technique

- Upper Extremity
- Foot
- Pediatrics

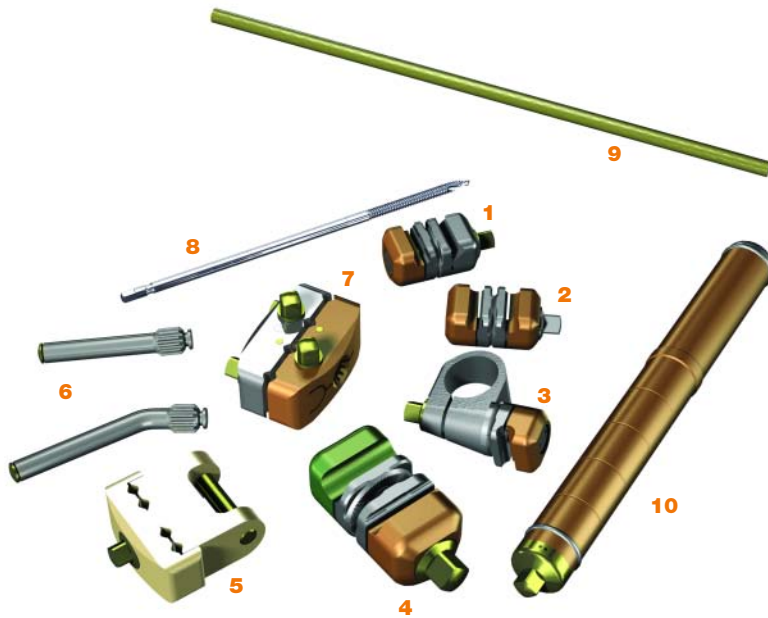


Raising the Bar Once Again

Table of Contents

System Components	01
Features & Benefits	02
Introduction	03
Frame Building Guidelines	04-05
Pin Insertion Guidelines	06
Frame Recommendations	07
Indications	08
Bridging Frames	09
Bridging Frame Technique	10-12
Non-Bridging Frames	13
Non-Bridging Frame Technique	14-17
Post Operative Rehabilitation and Pin Site Care Recommendations	18
Ordering Information – Components	19-20

System Components



1. Pin to Rod Coupling
2. Rod to Rod Coupling
3. Tube to Rod Coupling
4. 5mm/8mm Rod to Rod Coupling
5. Peri-Articular Pin Clamp
6. 30° Angled or Straight Post
7. Multi-Pin Clamp
8. Apex® Self-Drilling Pins
9. 5mm Connecting Rods
10. Compression/Distracton Tube

Features & Benefits

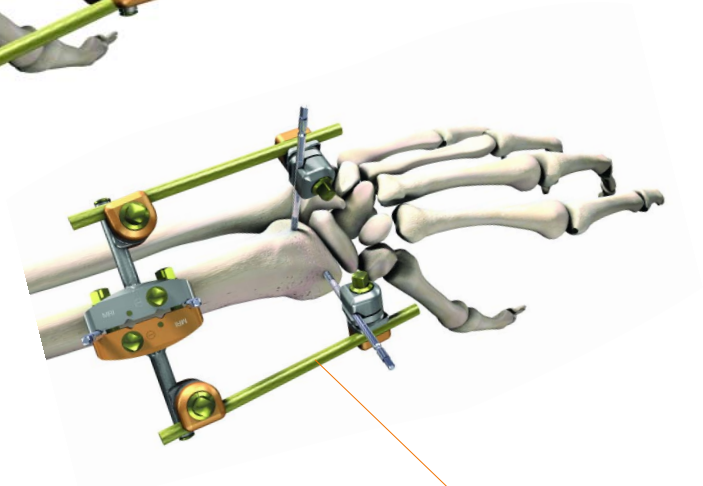
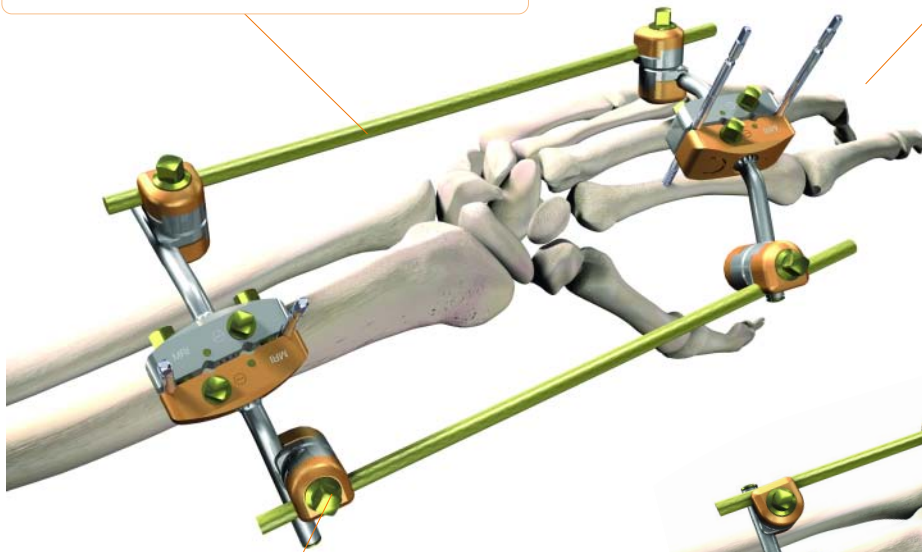
Versatility and ease-of-use are the keys to an effective external fixator. The Hoffmann® II Compact™ MRI System allows the surgeon to build a variety of joint bridging and non-bridging frames with simple modular components. The modularity of the System allows the surgeon to adapt the frame to patient size, soft tissue complications, and fracture pattern.

System Approach to MRI

All components in the System are designed for safety in the MRI environment. Patented light-weight and advanced composite materials are **non-ferromagnetic** and **non-conductive**.

Modular

Full System modularity allows the surgeon to build the frame to suit soft tissue and fracture requirements.



Easy to Use

Patented “Snap-Fit” technology makes stable frame building simple. Reduce the fracture, make post-operative adjustments, and treat soft tissue damage with the frame *in situ*.

Independent Pin Placement

With Independent Pin Placement, the surgeon may easily build a frame to treat fractures close to a joint, capture fracture fragments, or to stay clear of damaged soft-tissue areas.



Compatibility

The Hoffmann® II Compact™ MRI 5mm/8mm Rod to Rod Coupling is used to connect the Hoffmann® II Compact™ MRI 5mm Rods to a Hoffmann® II MRI 8mm Rod. This may be helpful in a Foot/Ankle Frame or to connect a humerus frame to a radius frame. The coupling is tightened with a 7mm Wrench.

Introduction

Fractures of the distal radius are common in adults and remain a challenge for the orthopaedic surgeon. Historically, the advent of external fixation as a technique for distal radius fracture management significantly improved treatment options, and external fixation is now considered a routine tool in the treatment of complex wrist trauma.

Stryker® was among the pioneers of external fixation in the wrist with the introduction of the Hoffmann® C-Series wrist and upper extremity fixator. With the advent of new technologies and new surgical materials, Stryker® built upon the success of the original Hoffmann fixator by introducing the Hoffmann® II External Fixation System. Recognizing the need for further enhanced surgery, Stryker® extended the Hoffmann® II External Fixation System by introducing the Hoffmann® II Compact™ MRI for use in the upper extremity, foot or pediatrics.

The Hoffmann® II Compact™ MRI fixator is designed to accommodate treatment of numerous fracture patterns by allowing independent movement of its clamps in multiple planes.

One of the main goals has been to reduce complexity of frame design, while providing total versatility and ease-of-use. The Hoffmann® II Compact™ MRI may be used with single pin placement or multi-pin clamps in a variety of frame configurations according to surgeon preference and fracture needs. The Hoffmann® II Compact™ MRI is truly designed to meet the needs of the patient and the surgeon.

In the wrist, intra-articular fractures with radio-carpal involvement may be treated with a bridging or trans-articular frame, whereas extra-articular fractures may be treated with a non-bridging or peri-articular frame.

Frame Examples

- Standard unilateral bridging frame
- Standard bi-lateral bridging frame
- Independent pin frame
- Peri-articular frame
- Radial osteotomy frame
- Foot frame
- Pediatric frame

Frame Building Guidelines¹

An understanding of external fixation principles requires a solid background in biomechanics. For years, research has shown that the biology of bone healing is significantly influenced by the biomechanics of fracture fixation.

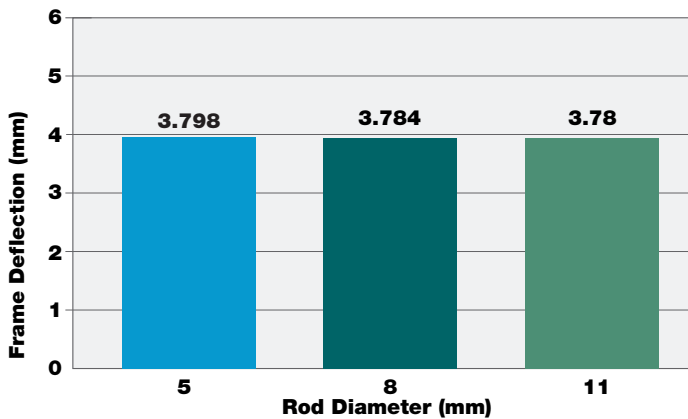
Two important properties to understand about the biomechanics of external fixation are stiffness and strength. Stiffness is defined as the measure of an external fixator's ability to resist deformation when loaded. Strength is defined as the measure of an external fixator's ability to resist failure under loads.

Not all frame components contribute equally to the overall strength and stiffness of a construct. **In general, external fixation pins are the most crucial elements of the fixator in creating successful external fixation frames.** An incremental change in connecting rod diameter or coupler properties will result in an insignificant change in frame stiffness and strength.

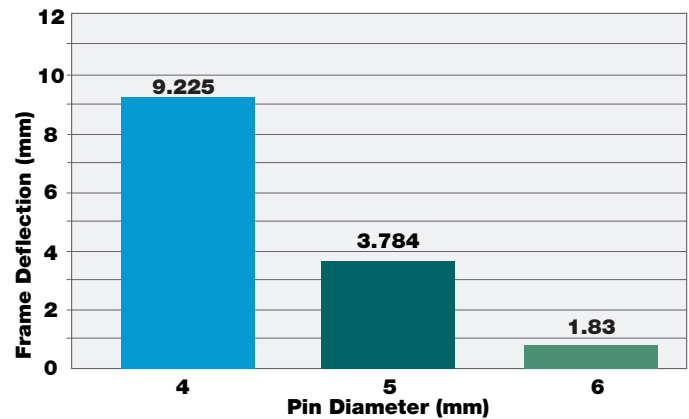
To help ensure strong, stiff, frames there are a few simple techniques that can be used when assembling an external fixator:

- increase the pin diameter
- increase the number of pins used
- keep the frame close to the bone
- space the pins far apart within a fragment

Ex Fix Frame Deflection vs. Rod Diameter (Pin Diameter = 5mm)



Ex Fix Frame Deflection vs. Pin Diameter (Rod Diameter = 5mm)



The effect of individual factors on frame stiffness:

Significant effect on improving frame stiffness

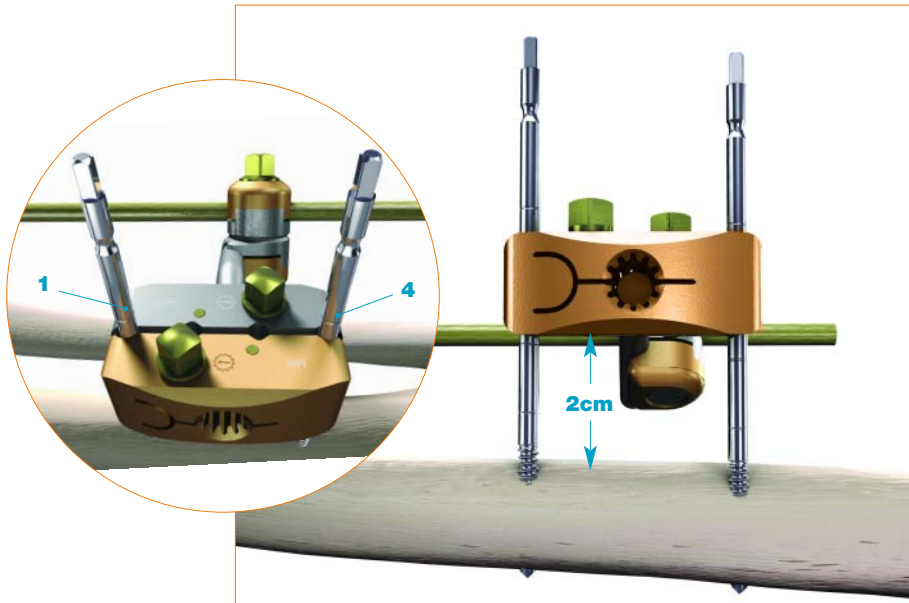
- Decreasing distance between frame and bone
- Increasing pin diameter
- Utilizing stiffer pin materials

Minimal effect on improving frame stiffness

- Increasing rod diameter
- Employing stiffer rod materials
- Applying stiffer clamp materials

1. Eric Ledet, PhD., Biomechanical Factors in External Fixation and Hybrid External Fixation. Stryker Whitepaper LSA48 2004

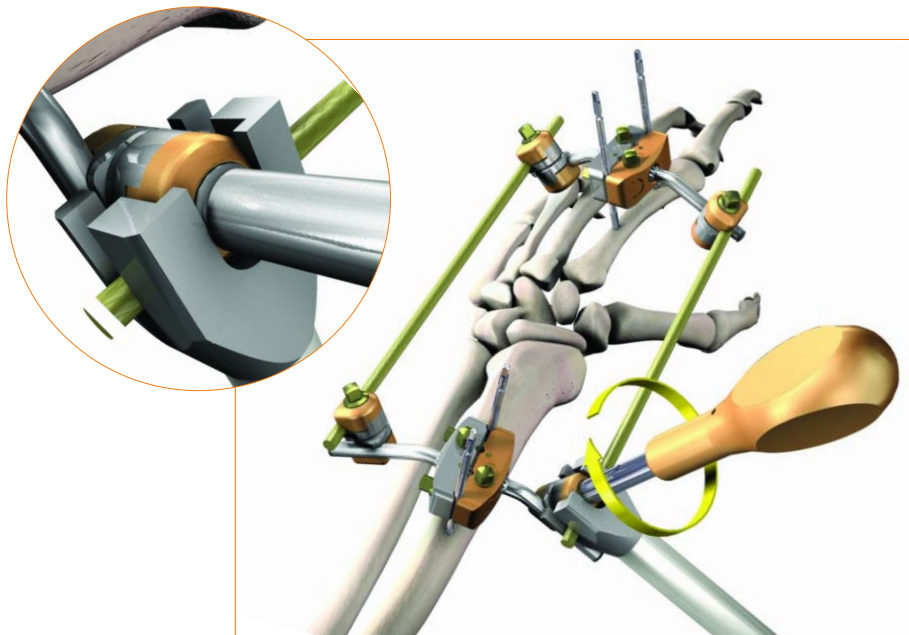
Frame Building Guidelines



The Multi-Pin Clamp is designed to build a variety of frames. If using two half pins within the clamp, use hole positions 1 and 4 when anatomy allows. This pin positioning creates the most stable construct.

Clamps and couplings should be placed far enough away from the skin to allow for post-operative swelling and proper pin site care (usually about 2cm).

Clamps are tightened with a 5mm wrench.



When tightening the clamps and couplings, it is important to apply sufficient torque to fully tighten the frame. It is also important to provide sufficient counter torque so that the tightening of the frame does not damage the pin/bone interface or disturb the fracture site. Make sure to hold onto the clamp or coupling to be tightened. This may be facilitated by using the Stabilization/Reduction Wrench as shown here.

The Stabilization/Reduction Wrench also allows the surgeon to keep their hands out of the x-ray field during fracture reduction.

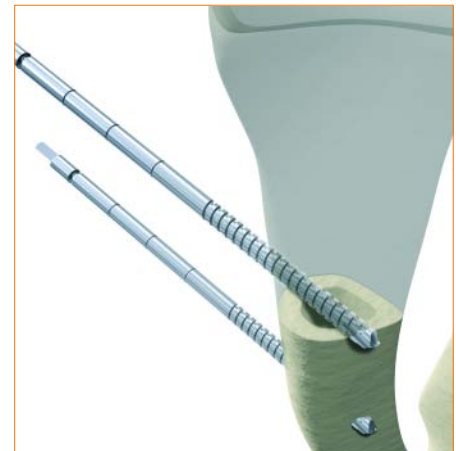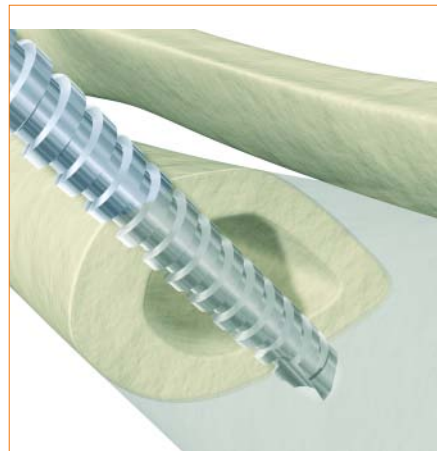
Pin Insertion Guidelines

The surgical techniques in this guide utilize the limited open approach for half pin insertion.

Two types of half pins are offered in the system: Blunt/Self-Tapping and Self-Drilling/Self Tapping. Pre-drilling is necessary when using Blunt/Self-Tapping half pins. It is optional to pre-drill when using Self-Drilling/Self-Tapping half pins.

- Use a 2.2mm Drill to pre-drill a 3mm half pin
- Use a 3.2mm Drill to pre-drill a 4mm half pin

The System supports 3mm and 4mm half pins; however, only 3mm pins should be used within the Peri-Articular Pin Clamp.



When inserting pins, ensure bi-cortical purchase.

Frame Recommendations

1. Fully open the Rod to Rod and Pin to Rod Couplings prior to attachment of the component to the frame.
2. All 5mm Square Head Screws should be positioned facing away from the patient and other frame components to make tightening more accessible.
3. When possible, place the Rod to Rod and Pin to Pin Clamps on the inside of the frame and facing the fracture to increase stability.
4. Connecting Rods should always be kept as short as possible in order to maximize frame stability.
5. Placing 30 Degree Posts facing downward will create a lower-profile frame.
6. As with all external fixation frames, the frame must be adapted to the weight and fracture patterns of the patient.
7. Precise reduction is not required prior to pin insertion. The frame can be assembled and the final reduction performed with the frame *in situ* before all components are locked in place.
8. During frame removal, use a quarter turn forward before backing the pins out to engage the cutting edge of the pin and facilitate pin removal.
9. Do not place Rod to Rod or Pin to Rod Couplings on the curved portions of the Curved Rod or 30° Angled Post.

Indications

Due to its versatility, the Hoffmann® II Compact™ MRI System is indicated for fracture fixation in pediatrics, upper extremity and foot. The specific indications for external fixation devices include, but are not limited to:

- Bone fracture fixation
- Osteotomy
- Arthrodesis
- Correction of deformity
- Revision procedure where other treatments or devices have been unsuccessful
- Bone reconstruction procedures

Upper Extremity

In the upper extremity, specific indications for the Hoffmann® II Compact™ MRI include fractures (whether AO Classification type A, B, or C fractures or Frykman classification type I through VIII fractures) that are unstable, secondary to intra-articular involvement, extra-articular involvement with some degree of radial sensory nerve dysfunction and loss of grip strength, unacceptable tilt or shortening, e.g., the ‘Colles’ fracture with dorsal angulation and shortening.

Other upper extremity indications for the Hoffmann® II Compact™ MRI include intercarpal fracture-dislocations (requiring intra- and/or postoperative stabilization), unstable forearm fractures associated with massive soft-tissue loss (e.g., secondary to gunshot wounds or arterial injuries) or unstable elbow dislocations, and multiple extremity fractures. The latter, including humerus, elbow, forearm, and hand fractures, may be managed with external fixation on an emergent basis while attention is directed to the other, more urgent injuries, such as vascular trauma.

The longevity of the treatment is predicated on the indication. Peri-Articular fractures of the distal radius may require 6 – 8 weeks of external fixation, whereas diaphyseal fractures of the distal radius (humerus) may require 2 – 3 months of immobilization in an external fixator.

Lower Extremity

Other indications for the Hoffmann® II Compact™ MRI exist in the lower extremity, particularly in the foot where there is a tendency for fracture shortening, e.g. unstable metatarsal fractures not amenable to open reduction and internal fixation. Massive bone loss from crush or gunshot injuries can be effectively managed by the Hoffmann® II Compact™ MRI, which provides the necessary distraction and access for reconstructive procedures.

In addition, for soft tissue injuries about the ankle and foot that are not associated with fractures, the Hoffmann® II Compact™ MRI can maintain the foot in a dorsiflexed position and allow suspension to prevent or decrease swelling. The Hoffmann® II MRI fixator for tibia fractures may be used in combination with the Hoffmann® II Compact™ MRI to incorporate the foot and prevent soft-tissue motion about the fracture site.


In summary, the Hoffmann® II Compact™ MRI has a place in the management of fractures and soft tissue injuries whenever wound access is necessary, inherent instability prevails, or rapidity of application and urgent stabilization is a factor.

Contraindications


See package insert for a full description of warnings, precautions, adverse events and contraindications.

Bridging Frames

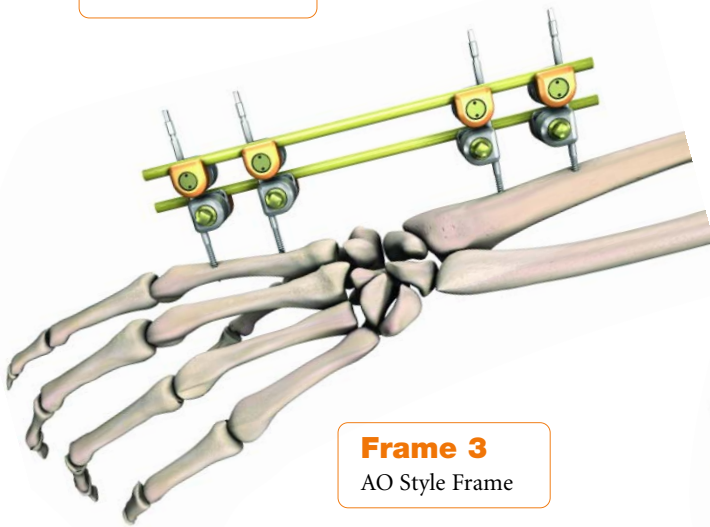
It is possible to build many frame configurations using the Hoffmann® II Compact™ MRI. The frame building guidelines listed on page 4 may be applied to building any frame configuration. This section will illustrate construction of Bridging Frame 1, below.



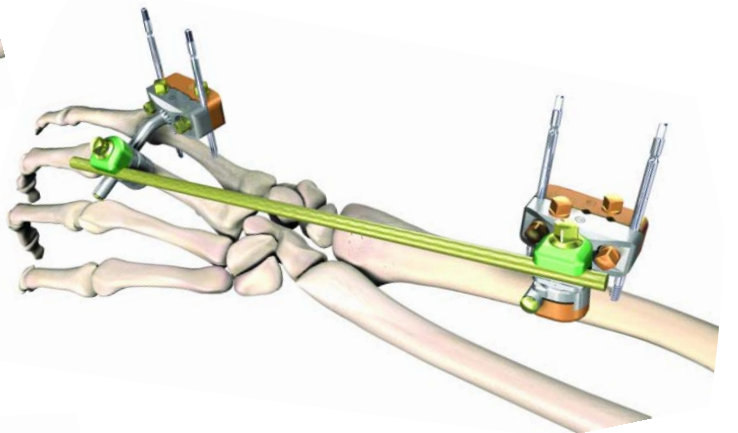
Frame 1
Standard Box Frame



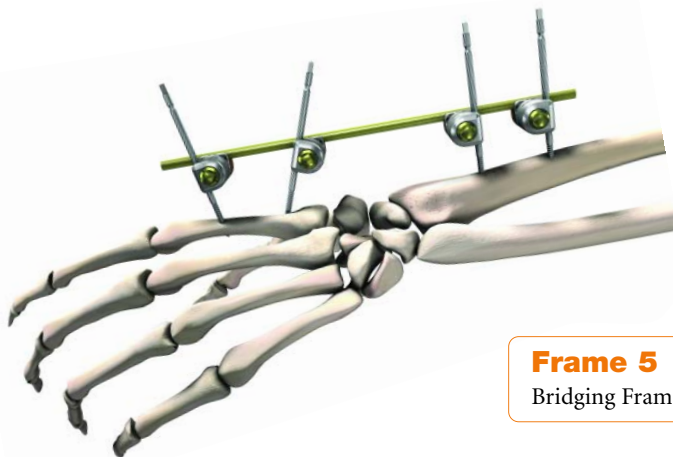
Frame 2
Lower Profile Frame



Frame 3
AO Style Frame



Frame 4
Frame with an 8mm rod



Frame 5
Bridging Frame with angled pins

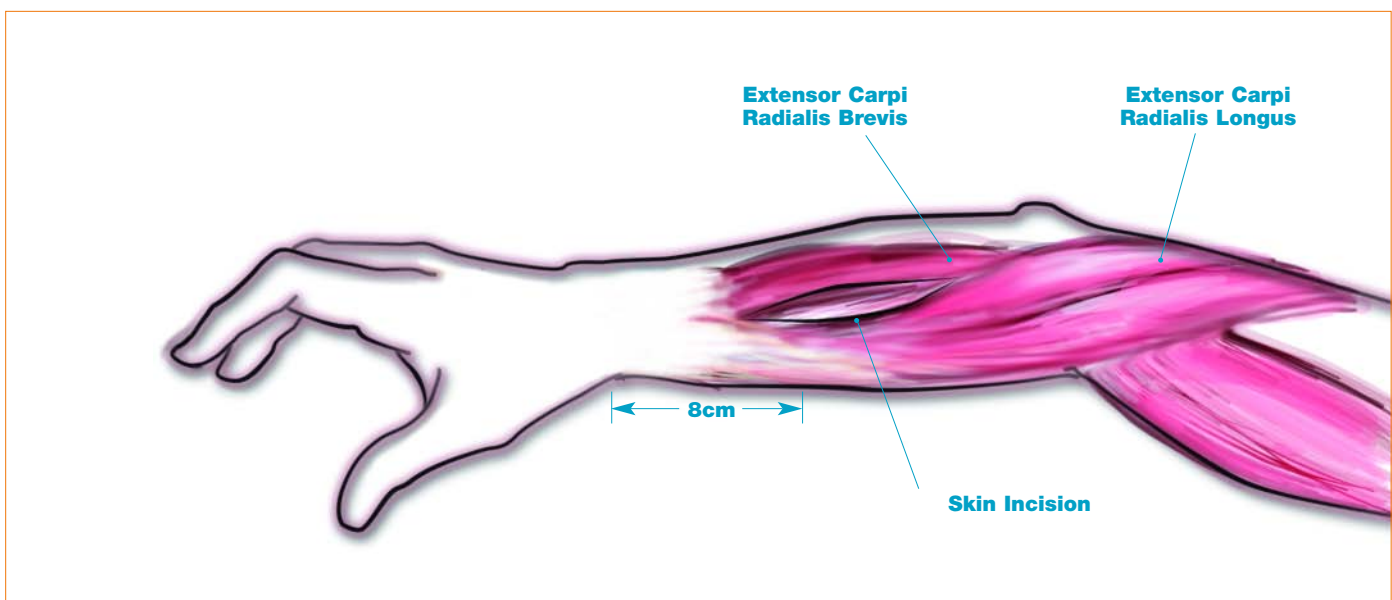
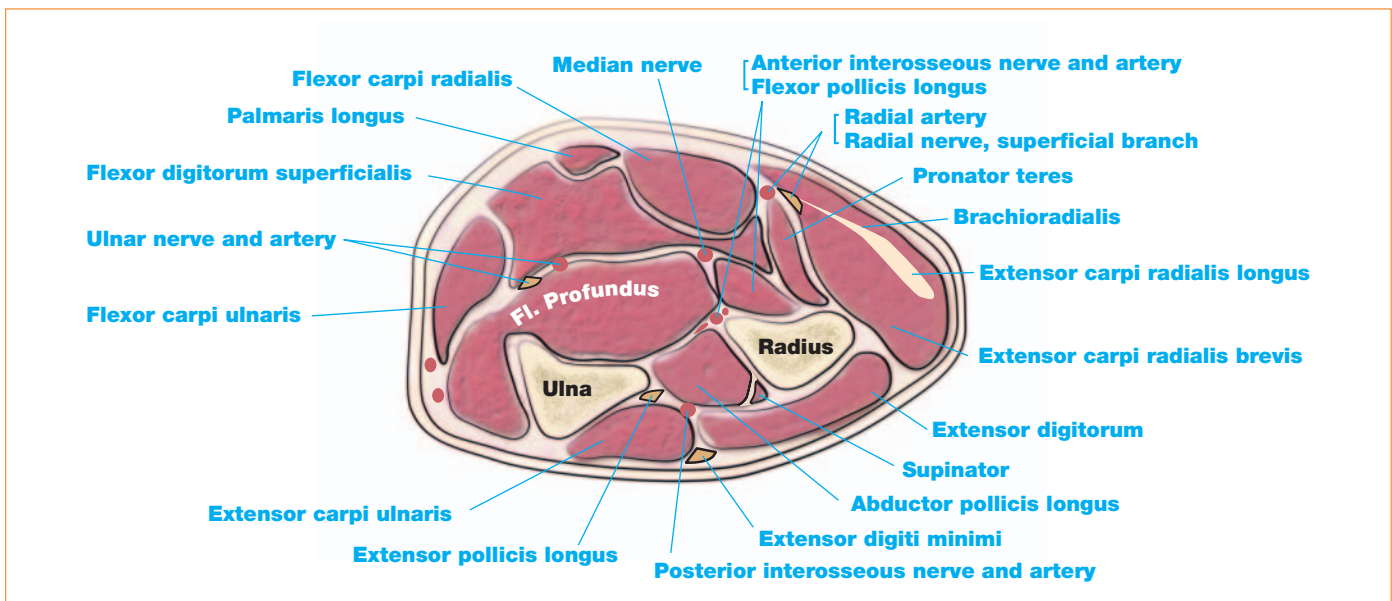
Bridging Frame Technique

Treatment of distal radius fractures begins with the evaluation of the initial radiographs. Injury radiographs will demonstrate the degree of dorsal tilt and angulation, giving an indication of the degree of stability and potential success of closed treatment.

The greater the degree of dorsal tilt, comminution, and displacement, the greater the indication for operative intervention. Preliminary closed reduction films, preferably in traction, will allow evaluation of the articular alignment, again indicating the degree of step-off and the need (if any) for intra-articular realignment.

Once reducibility is confirmed, the level of care and need for surgical intervention will be determined. The external fixator affords a treatment option for those patients with the potential for recurring deformity and displacement. Through reduction obtained by ligamentotaxis, the external fixator (usually worn for 6 to 8 weeks) allows optimization of hand and arm motion, without requiring casting.

Safe Pin Zones



Bridging Frame Technique

Step 1

The external fixator is applied under sterile conditions using a tourniquet.

Proximal Pin Placement in the Radius

The proximal pin group should be at least 6 centimeters from the distal radial joint and pins should be inserted through an open or mini open incision (Figure 1).

The pins should be perpendicular to the long axis of the bone. Pin placement should range from 10 to 60 degrees dorsal radial, while ensuring bi-cortical purchase (Figure 2). Pre-drilling is necessary when using Blunt/Self-Tapping pins.

Note:

It is recommended to use three Apex® half pins. Occasionally, one pin will require removal and the two remaining pins will afford stability through the remaining life of the fixator. Soft tissue protection is recommended.

A Pre-Drilling Assembly Trocar is available and may be used with a Drill Guide (Figure 3A) or placed directly into the Multi-Pin Clamps to ensure proper pin spacing and tissue protection (Figure 3B).

Distal Pin Placement

Distal pin placement should range from 0 to 60 degrees dorsal radial, while ensuring bi-cortical purchase (Figure 4).

If preferred, the proximal pin may be inserted through the second metacarpal into the base of the third metacarpal. This provides six cortices of pin purchase. In this case the pin placement should range from 0-5 degrees dorsal radial to the frontal plane.

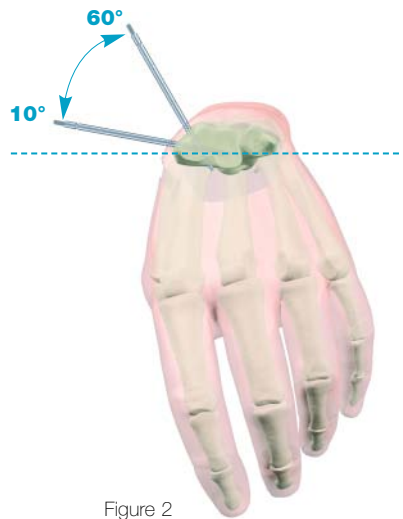


Figure 2

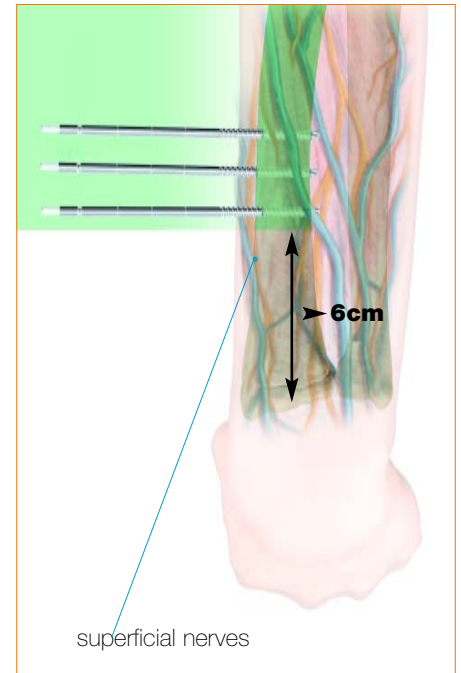


Figure 1

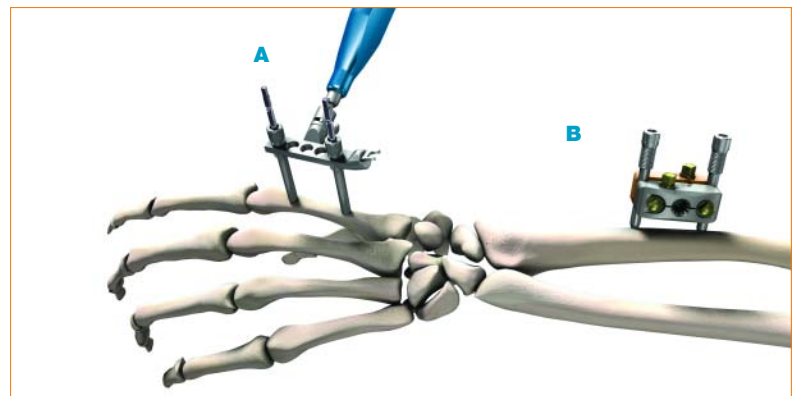


Figure 3

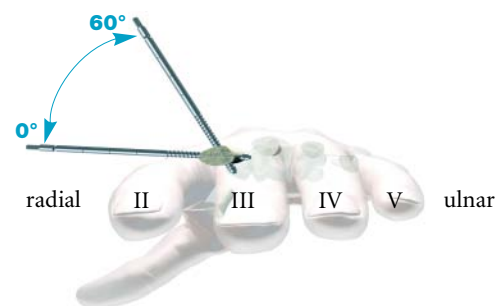


Figure 4

Bridging Frame Technique

Step 2

After accurate pin placement is confirmed and before construction of the frame, the incisions are closed. Position two Multi-Pin Clamps onto the half pins. Tighten Bolts A to secure the Clamps to the half pins (*Figure 5*).

Step 3

Insert two Straight or 30° Angled Posts into each of the pin clamps. Tighten Bolts B to secure the Posts (*Figure 6*).

Note:

The Posts may be placed in twelve different positions within the pin clamp. This may be helpful as the frame should not obstruct thumb movement. The Posts may be placed in the Clamp prior to Step 3 if preferred.

Step 4

Connect the Rod to Rod Couplings to the Posts and 5mm Connecting Rods (*Figure 7*). Unrestricted multi-planar motion of the frame allows for manipulation of the fracture with the fixator in place. Closed reduction is carried out, and final reduction confirmed with x-ray. The degree of traction applied during reduction should create “physiologic” tension across the intact tissue sleeve.

It is very important to avoid over-distracting. Ensure that there is no over-distraction in the midcarpal joint and that the tension provided by the fixator increases the normal width of the radiocarpal joint by no more than 1mm.¹

Step 5

When relatively normal length, angulation and rotational alignment are restored, secure all planes by firmly tightening Bolts C on the Rod to Rod Couplings (*Figure 7*). Also ensure that all bolts on the Multi-Pin Clamps and Rod to Rod Couplings are securely tightened. Pin Caps may be placed on the half pins for patient protection. The final frame is shown in *Figure 8*.

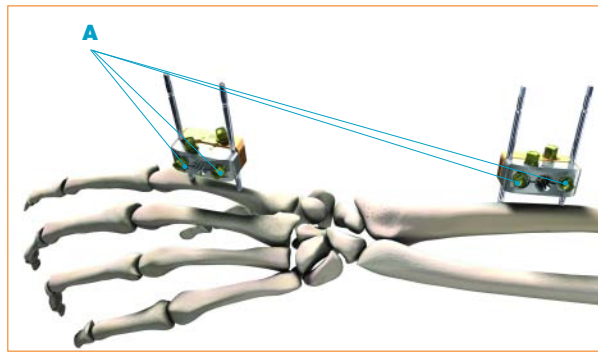


Figure 5

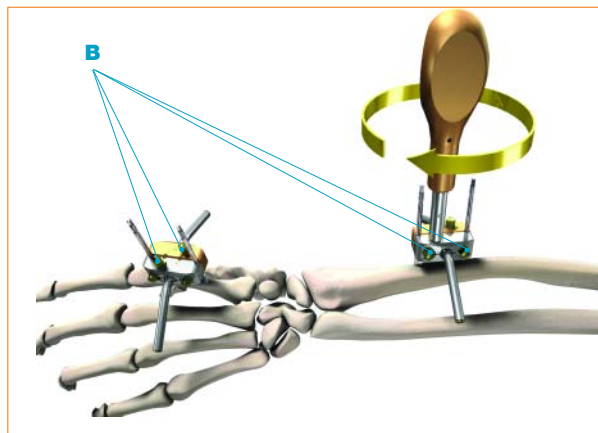


Figure 6

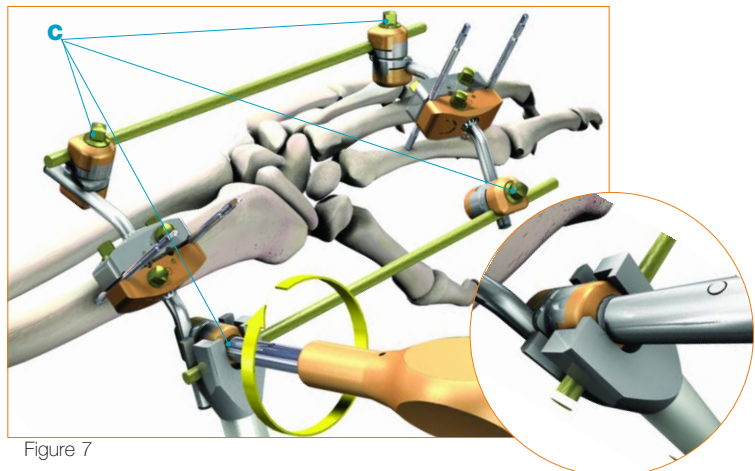


Figure 7

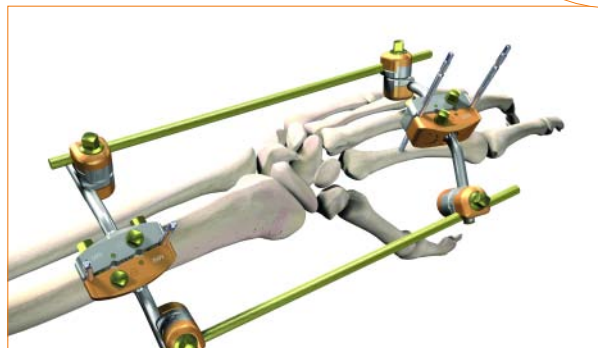
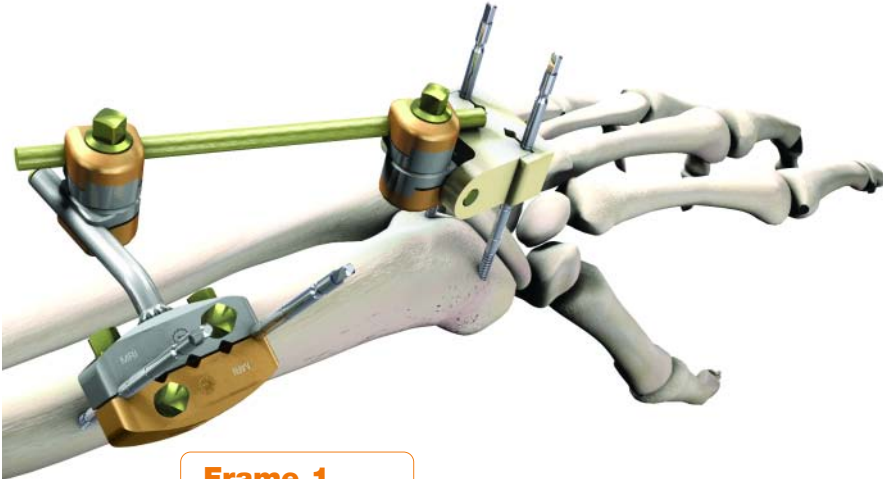


Figure 8

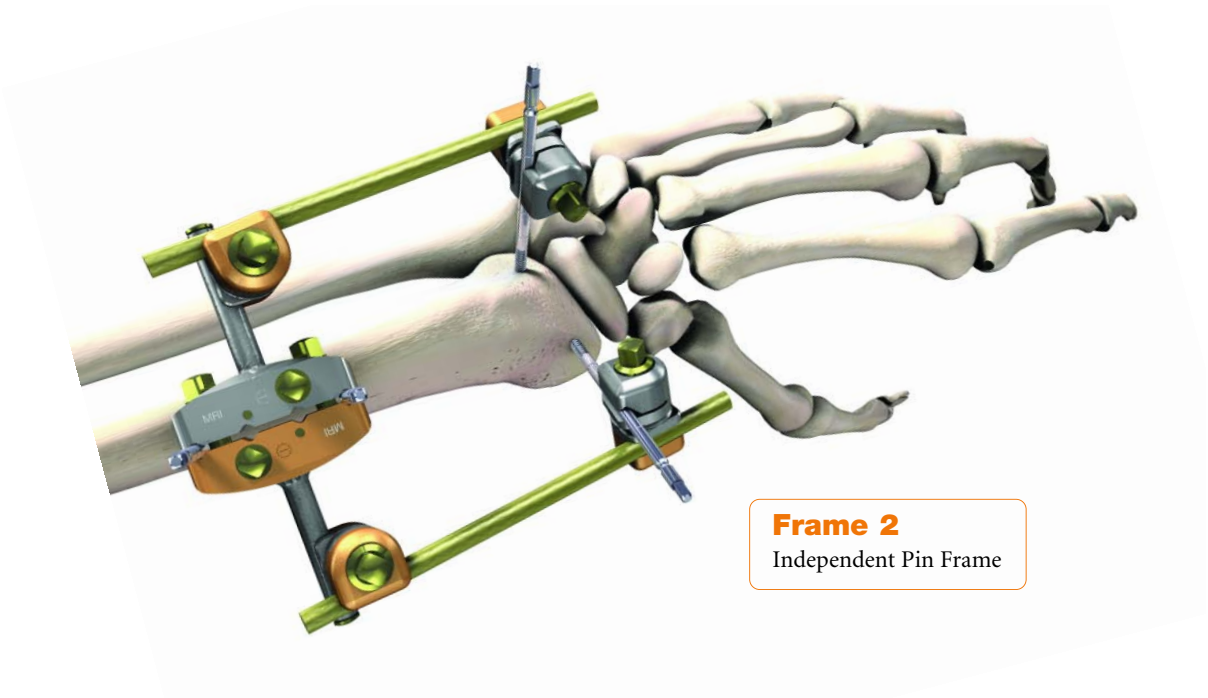
1. Seitz, WH JR. Perils and Pitfalls of External Fixation for Distal Radius Fractures. *Techniques in Orthopaedics*. 15(4):305-314 pp 305-313 2000

Non-Bridging Frames

It is possible to build many frame configurations using the Hoffmann® II Compact™ MRI. The frame building guidelines listed on page 4 may be applied to building any frame configuration. This technique will illustrate construction of the standard non-bridging frame below.



Frame 1
Standard Frame



Frame 2
Independent Pin Frame

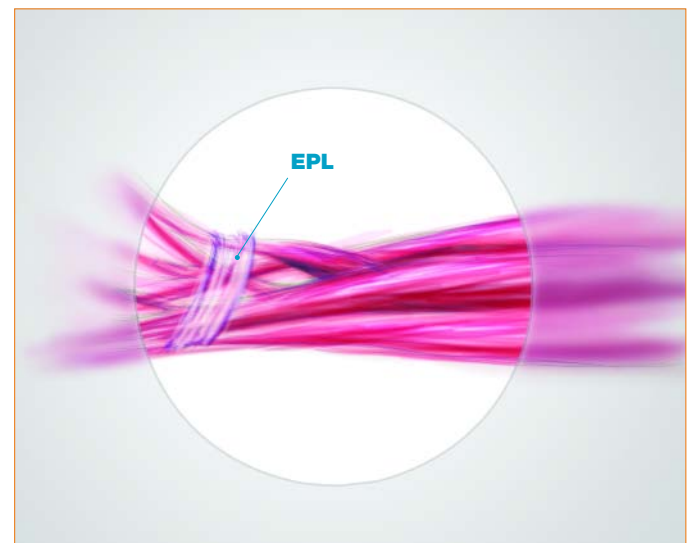
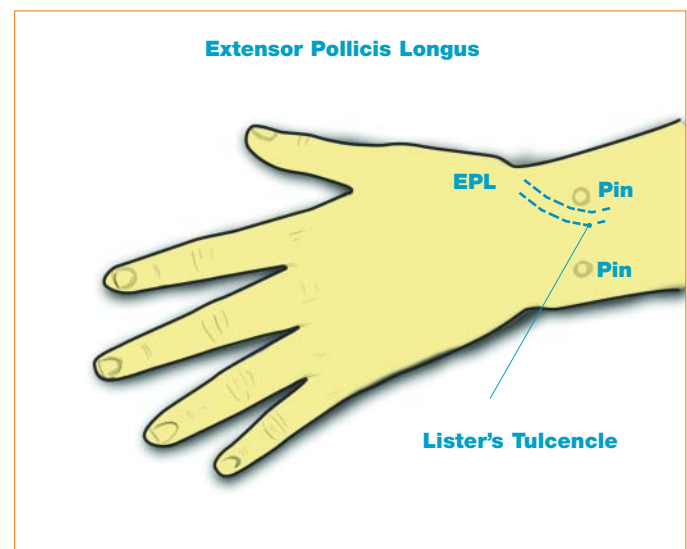
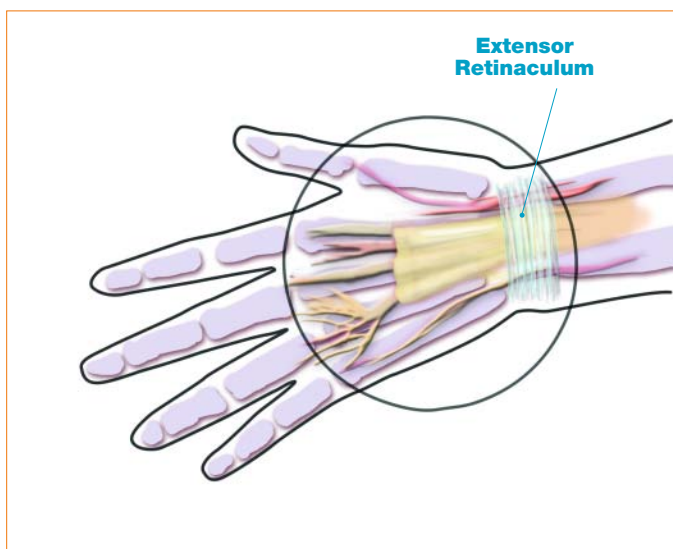
Non-Bridging Frame Technique

Non-bridging frames are often used in the following indications:

- Unstable extra-articular fractures of the distal radius
- Open and comminuted extra-articular fracture
- Unstable distal radial fractures with undisplaced single articular extension
- Distal radial osteotomies

This technique should only be used where there is sufficient space in the distal part of the fracture to insert the pins of the frame. This usually requires 1cm of volar cortex and an intact or reconstructed joint surface.¹

Safe Pin Zones



1. Management of Open Fractures - C. Court-Brown, M. McQueen, A. A. Quaba - Martin Dunitz Edition

Non-Bridging Frame Technique

Step 1

Peri-Articular Pin Placement

Peri-Articular pin placement is used with Non-bridging frames. There should be at least 1 centimeter of volar cortex and an intact or reconstructed joint surface.

Soft tissue protection is recommended. A Pre-Drilling Assembly (trocar) is available and may be used with a Drill Guide (Figure 9) or placed directly into the Pin Clamp (Figure 10) to ensure proper pin spacing and soft tissue protection.

When using the Peri-Articular Pin Clamp, two pins are inserted on either side of Lister's Tubercle parallel to each other through a mini open incision avoiding damage to the Extensor Pollicis Longus tendon (EPL).

The pins should be parallel to the radiocarpal joint surface (Figure 11).

If full independent pin placement is required, a half pin may be placed proximal to the radial styloid and parallel to the radial carpal joint in the AP view.

In this region, care must be taken to avoid the radial nerve and other soft tissues; sharp dissection is not recommended.

Note:

Take care not to damage the Extensor Pollicis Longus or other tendons, nerves, or vessels.

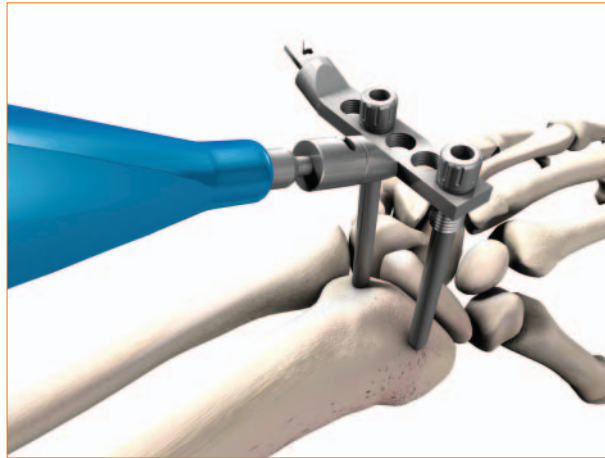


Figure 9




Figure 10

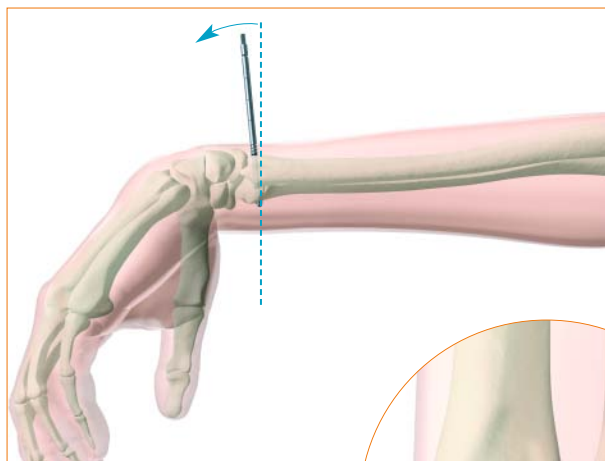


Figure 11

Non-Bridging Frame Technique

Step 2

Proximal Pin Placement in the Radius

The proximal pin group should be at least 6 centimeters from the distal radial joint and pins should be inserted through an open or mini-open incision (Figure 12).

The pins should be perpendicular to the long axis of the bone. Pin placement should range from 10 to 60 degrees dorsal radial, while ensuring bi-cortical purchase (Figure 13). Pre-drilling is necessary when using Blunt/Self Tapping pins.

Take care to avoid the radial nerve, blood vessels, and other soft tissues. Sharp dissection is not recommended.

Under power or using the 5mm Wrench/Pin Driver, insert two to three Apex® half pins (Figure 14). The placement of three half pins allows the surgeon to remove a pin, if needed, due to loosening or infection, and maintain frame stability. Confirm half pin placement under x-ray.

Step 3

For the proximal pin group, this technique describes using a Standard Pin Clamp. A Peri-Articular Pin Clamp may be used if preferred. Ensure pin placement corresponds to the holes in the clamp selected (Figure 15).

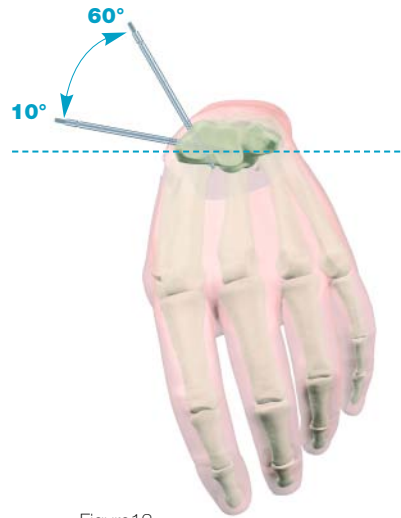


Figure13

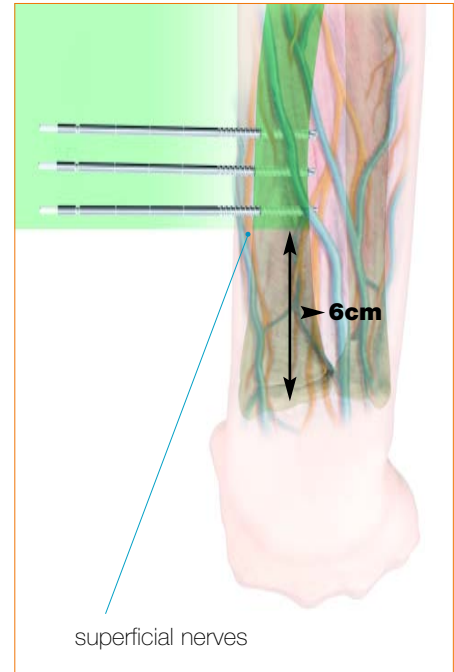


Figure 12

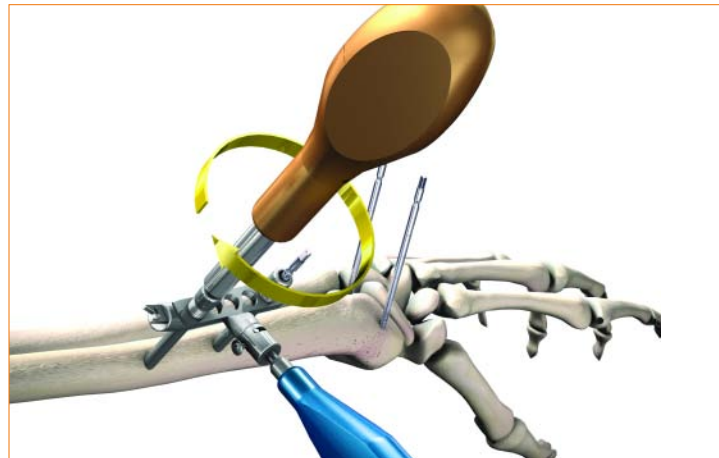


Figure14

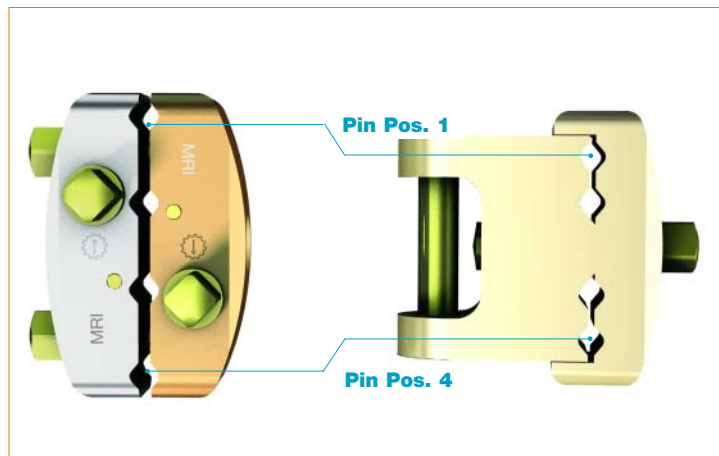


Figure15

Non-Bridging Frame Technique

Step 4

Assemble a Peri-Articular Pin Clamp with the distal half pins and a standard Pin Clamp to the proximal half pins. The Peri-Articular Pin Clamp bolt must face distally. Tighten Bolts A to secure the clamps to the pins (*Figure 16*).

Step 5

Insert a Straight or 30° Angled Post to the standard Pin Clamp and tighten Bolt B to secure it to the clamp (*Figure 17*).

Note:

This may be done prior to Step 5 if preferred.

Step 6

Attach a Rod to Rod Coupling to each Pin Clamp, and connect the two Rod to Rod Couplings with a 5mm connecting rod (*Figure 18*). Unrestricted multi-planar motion of the frame allows for manipulation of the fracture with the fixator in place. Closed reduction is carried out, and final reduction confirmed with x-ray.

Step 7

When relatively normal length, angulation and alignment are restored, ensure that all bolts on the Pin Clamps and Rod to Rod couplings are securely fastened. Check final reduction under x-ray. Pin caps may be placed on the half pins for patient protection. Final frame configuration is shown in *Figure 19*.

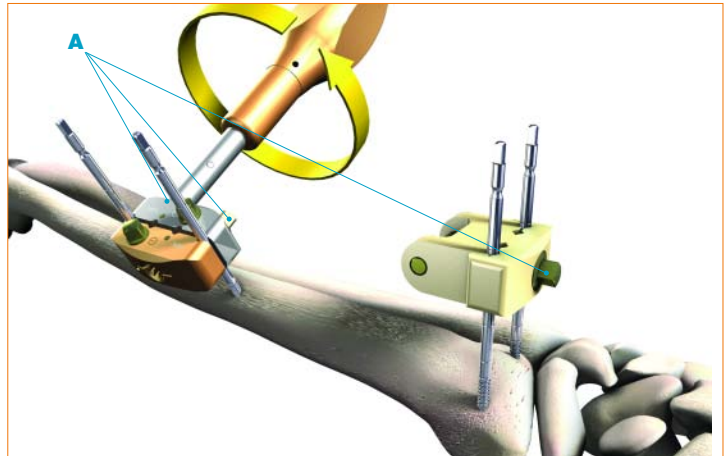


Figure 16

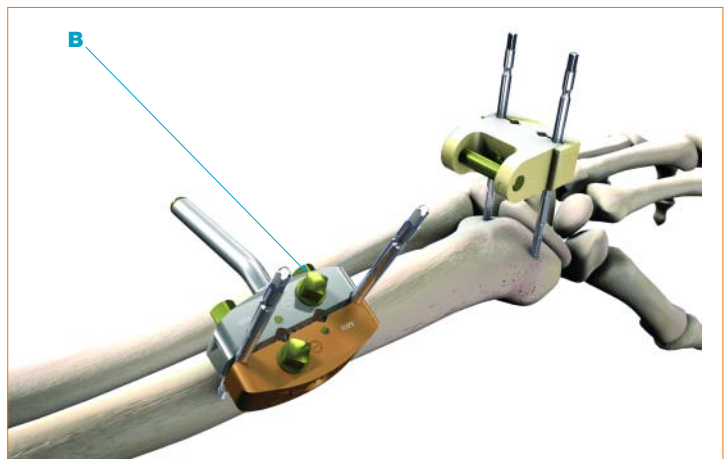


Figure 17

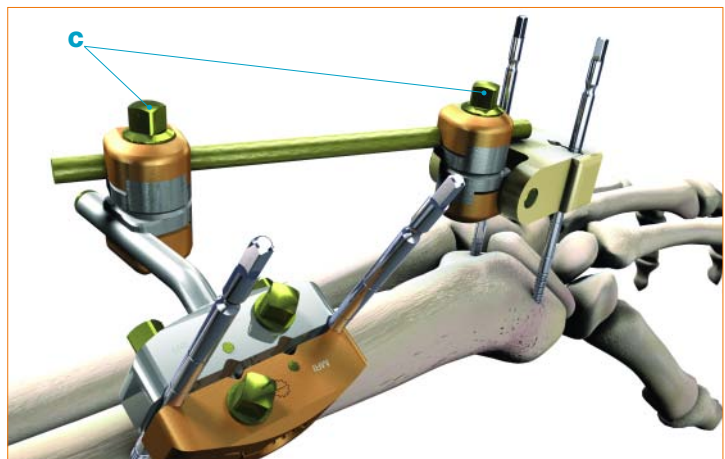


Figure 18

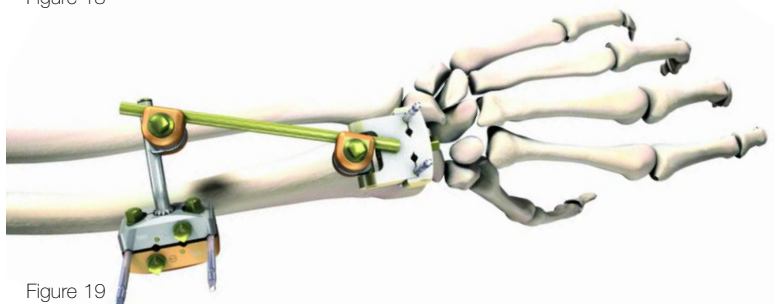


Figure 19

Post Operative Rehabilitation and Pin Site Care Recommendations

Before surgery, it is helpful to gain patient understanding and commitment to post-operative pin site care and rehabilitation activities that will be required of them. To assist in External Fixation patient education, Stryker offers a patient education brochure; for ordering information contact your Stryker sales representative.

Before leaving the operating room a bulky, comfortable, compressive, soft dressing is applied around the hand and wrist which allowing full finger mobility. Patients are instructed in active range of motion of all free joints by a trained hand therapist in the ambulatory recovery area. They are encouraged to actively use the hand in activities of daily living and are instructed to keep the hand and dressing clean and dry, avoiding any contamination of the pin sites.

On the fifth (5th) post-operative day, patients are seen back and the surgical dressing is removed. At this point the patient is instructed in pin site care consisting of careful cleansing of the pin sites with a sterile cotton swab with hydrogen peroxide used to break up clotted and crusted blood. This is performed TWICE DAILY over the ensuing week, providing adequate dissolution of dry, coagulated blood and allows normal serous “weepage” around the pins until wound healing has been achieved.

On the twelfth (12th) post-operative day sutures, which had been placed around the pin sites, are removed and cleansing is now performed TWICE DAILY with alcohol. If there is some crusting around the pin sites, a preliminary cleansing can be performed with peroxide prior to cleaning with alcohol. The alcohol tends to dry out the area around the pin sites and helps prevent pin site infection.

From this point forward patients are allowed to once daily have clean running water flow over the fixator and pins in the shower following which the pin sites are dried with a clean gauze pad and then the previously mentioned pin site cleansing is performed with alcohol.

It is imperative during this post-operative period that active range of motion of all free joints is performed. This allows tendons to glide over areas of injury without forming adhesions and keeps capsular ligaments flexible avoiding late contracture. Functional hand use is encouraged so that at the point of healing when the fixator is removed the patient is able to transition rapidly into advanced activities of daily living. Depending upon the underlining injury and degree of adjunct surgery, the fixator and its imbedded half pins are usually removed in the office without any need for sedation at a period four (4) to six (6) weeks following surgery. Pin sites close over rapidly within twenty-four (24) hours and the only dressing used for the first twenty-four (24) hours after removal is a band-aid, following which the pin sites are left open to the air.

Adjunct thermoplastic splinting is sometimes used for support after removal of a spanning wrist fixator for an additional four (4) weeks until the patient regains active wrist control.

Intrinsic stretching, tendon gliding, maintenance of forearm musculature, and shoulder and elbow range of motion are of paramount importance during the early healing phase while the external fixator is in place.¹

Follow-up radiographs will dictate the timing for fixator removal (average approximately 7 weeks).

Pin Site Care Summary

Begins the day after surgery, and will vary based on surgeon preference.

However, two common pin site regimens are summarized below:

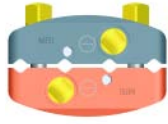
- Twice-daily cleansing with peroxide for the first week and twice-daily cleansing with alcohol thereafter for the remainder of the fixation period.¹
- Three times a day cleaning with a mixture of hydrogen peroxide and normal saline.²

1. Seitz, WH JR. Perils and Pitfalls of External Fixation for Distal Radius Fractures. *Techniques in Orthopaedics*. 15(4):305-314 pp 305-313 2000
2. Seligson, D; Asche, G. Stryker Patient Education Brochure. Lit Number LEFPCB

Ordering Information – Components

REF Description

Hoffmann® II Compact™ MRI Components



4941-2-020 4-Hole Pin Clamp for 3 and 4mm pins



4941-2-200 Peri-Articular Pin Clamp for 3mm pins




4941-1-010 Rod to Rod Coupling for 5mm rods or posts



4941-1-020 Pin to Rod Coupling for 5mm rods or posts/3-4mm pins



4941-1-058 Rod to Rod Coupling for 8mm rods or posts/5mm rods or posts



4941-1-100 Tube to Rod Coupling for 15mm tube/5mm rods or posts



4941-2-140 30° Angled Post, 5mm



4941-2-120 Straight Post, 5mm

Hoffmann® II Compact™ MRI 15mm Tube



4941-0-015 Compression/Distracton Tube

5mm Rods



5048-5-065 Carbon Connecting Rod 65mm



5048-5-100 Carbon Connecting Rod 100mm



5048-5-150 Carbon Connecting Rod 150mm



5048-5-200 Carbon Connecting Rod 200mm



5048-5-250 Carbon Connecting Rod 250mm



5048-5-300 Carbon Connecting Rod 300mm

Ordering Information – Components

REF

Description

Hoffmann® II Compact™ MRI Instruments

(not for use in the MRI suite)



4940-9-010

Stabilization/Reduction Wrench



5057-1-003

Quick Release Apex® Chuck with AO fitting, 3mm



5057-1-004

Quick Release Apex® Chuck with AO fitting, 4mm



4920-9-020

Thumbwheel



4940-9-030

5mm Wrench/3-4mm Pin Driver



5057-1-110

Drill Guide Handle



5057-1-117

Drill Guide Block, 4 hole, Hoffmann® II Compact™




5057-1-118

Drill Guide Block, 4 hole, Hoffmann® II Compact™
Peri Articular Clamp



5150-9-005

5mm Spanner Wrench



4941-9-923

Storage Case Lid



4941-9-922

Storage Case Insert



4941-9-926

Storage Case Base

Notes

Joint Replacements

Trauma, Extremities & Deformities

Craniomaxillofacial

Spine

Biologics

Surgical Products

Neuro & ENT

Interventional Pain

Navigation

Endoscopy

Communications

Imaging

Patient Handling Equipment

EMS Equipment

Manufacturer:

Stryker GmbH
Bohnackerweg 1
CH - 2545 Selzach
Switzerland

www.stryker.com

The information presented in this brochure is intended to demonstrate the breadth of Stryker product offerings. Always refer to the package insert, product label and/or user instructions before using any Stryker product. Products may not be available in all markets. Product availability is subject to the regulatory or medical practices that govern individual markets. Please contact your Stryker representative if you have questions about the availability of Stryker products in your area.

The marks bearing the symbol [™] are trademarks of Stryker.
The marks bearing the symbol [®] are registered trademarks of Stryker.

Content ID: H-ST-30, 12-2015 (Former Literature Number : LH2MRI-CST).
This document is solely approved for use in the US. The corresponding version outside of the US is H-ST-21.